

M P MEDICAL SCIENCE UNIVERSITY, JABALPUR
MARKSHEET

Name of Examination & Year : BDS IV Year Examination March-2023

Name Of College: Rishiraj College of Dental Sciences and Research Centre, Bhopal (DP010)

Course : BDS

Date Of Exam :

Subject Name : Periodontics

S. No	Enrollment No	Roll No.	Student's Name	Practical	Internals		Viva- Voce	Theory	
					Practical Internal	Theory Internal		Paper A	Paper B
					90	10		10	20
1									
2									
3									
4									
5									
6									
7									
8									
9									
10									
11									

Madhya Pradesh Medical Science University, Jabalpur
BDS Fourth Year Examination Feb-2021
Paper Code:- 21AD0100100901
Subject- Oral Medicine And Radiology

Maximum Marks : 70

Time : 3:00 Hours

Instructions:

- a) All questions are compulsory.
- b) Draw diagrams wherever necessary.
- c) Answers of Questions and Sub questions must be written strictly according to the serial order of question paper.
- d) MCQ has to be answered in theory answer book.
- e) Please write MCQ answer neatly and in serial order with black or blue pen in brackets for example:- 1. (a) 2. (b).
- f) MCQ has to be answered only once, any kind for repetition or cutting or erasing or whitener will be consider as malpractice, Such answers will not be counted in the marks and action will be taken according to UFM rules of University.
- g) Do not write anything on the blank portion of the question paper- such type of act will be considered as an attempt to resort to unfair means.

Q. 1 Total MCQs : 10

10 X 1 = 10

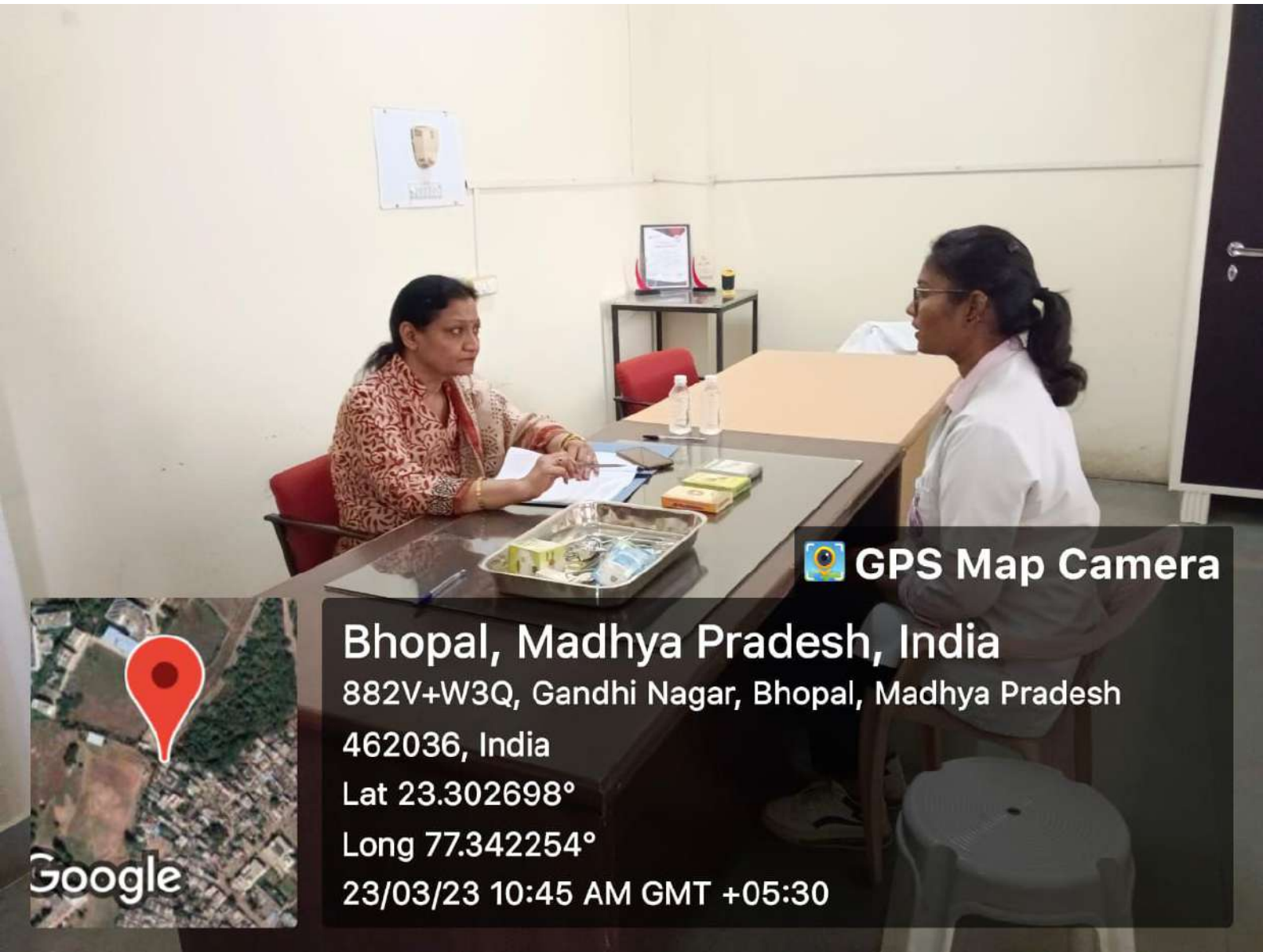- 1 Bone pain, renal calcinosis, and giant cell jaw lesions are most likely to be seen in which one of the following disorders?
 a. Acromegaly b. Fibrous dysplasia c. Hyperparathyroidism d. Hyperthyroidism
- 2 Clinical feature of submucous fibrosis.
 a. White patch b. blanching c. red patch d. None
- 3 Faults are
 a. Light radiograph b. Dark radiograph c. Emulsion peel d. All of above
- 4 A 55 y old female presents with SEVERE, ELECTRICAL and SHOCKING PAIN in her right cheek triggered by light touch. clinical examination does not reveal any local cause. Which drug is most likely to be effective for her?
 a. Ergotamine b. Paracetamol c. Carbamazepine d. Sumatriptan
- 5 which of the following is feature of secondary sjogren's syndrome?
 a. Dry eyes b. Dry mouth c. Anosmia d. Connective tissue disease
- 6 It is used to reduce the size of X-ray beam
 a. Filtration b. Collimator c. Film holder d. Film
- 7 Distance of working area from safe light
 a. 8 feet b. 4 feet c. 2 feet d. 10 feet
- 8 Carbamazepine indicated in:
 a. Trigeminal neuralgia b. leukoplakia c. all of above d. None
- 9 Size of IOPA film
 a. 31x41mm b. 31x41cm c. 31x41 inches d. None
- 10 Target lesions seen in
 a. Erythema Multiforme b. Myositis occificans c. Antrolith d. Phlebolith


Q.2 Long Answer Questions

- a. Classify Salivary Gland Tumors. Describe in detail about Sjogren's syndrome
- b. Classify cyst. Discuss about clinical features and radiographic features of dentigerous cyst.
- c. Classify Temporomandibular disorders. Describe about clinical features and management of Myofascial Pain Dysfunction Syndrome.
- d. Classify vesiculobullous lesions. Discuss in detail about pemphigus vulgaris.
- e. Biological Effects of Radiation

Q.3 Short Answer Questions

- a. Investigation and treatment of Candidiasis
- b. Laboratory investigation and Oral Manifestations of HIV
- c. Erythema Multiforme
- d. Clinical features and management of Leukoplakia
- e. Pernicious anemia
- f. Causes of dark radiograph
- g. Clinical features and management of Trigeminal Neuralgia.
- h. Management of Xerostomia
- i. Radiographic features of ameloblastoma
- j. Properties of X rays



 **GPS Map Camera**

Bhopal, Madhya Pradesh, India

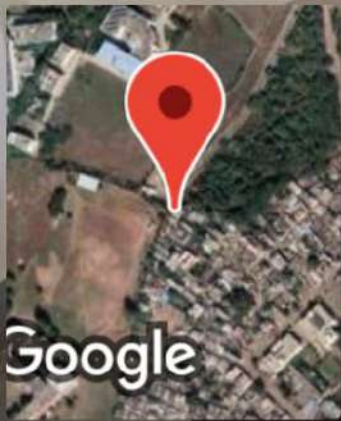
882V+W3Q, Gandhi Nagar, Bhopal, Madhya Pradesh

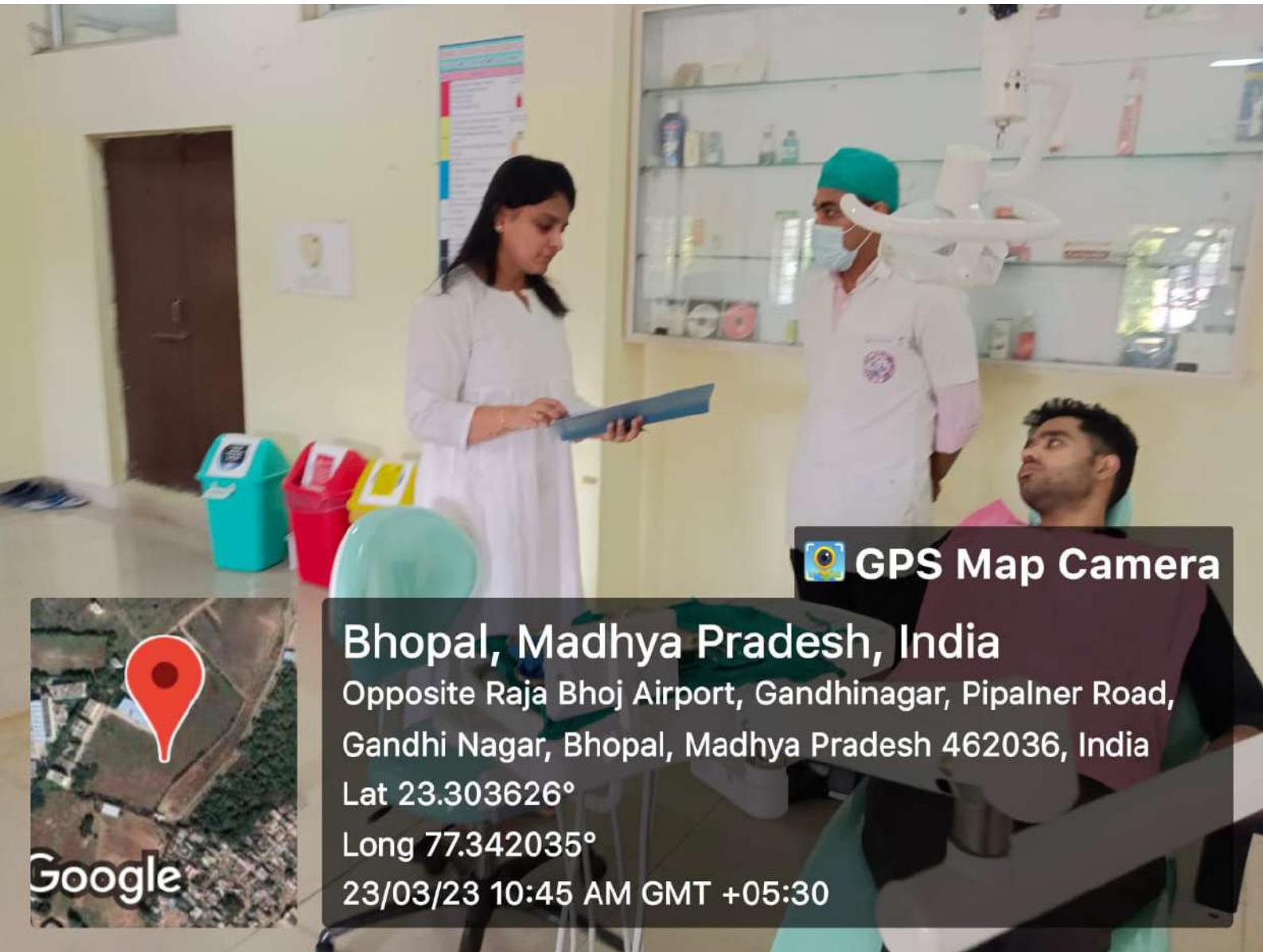462036, India

Lat 23.302698°

Long 77.342254°

23/03/23 10:45 AM GMT +05:30





 **GPS Map Camera**

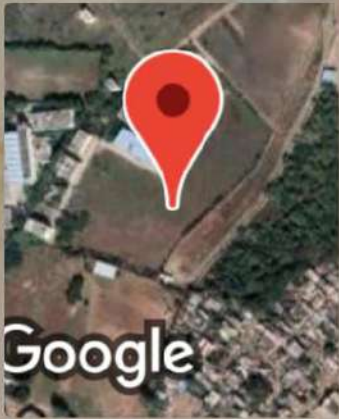
Bhopal, Madhya Pradesh, India

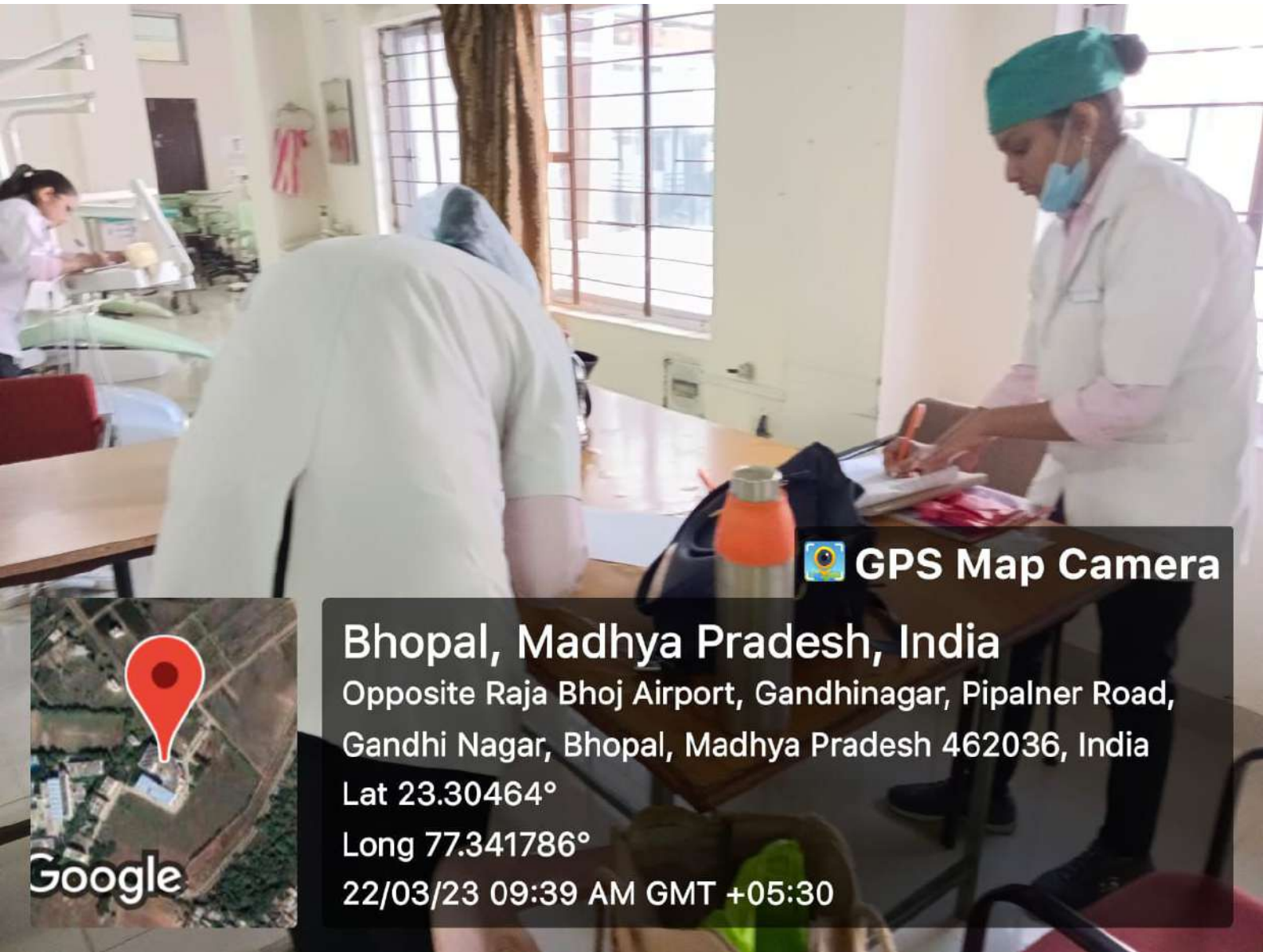
Opposite Raja Bhoj Airport, Gandhinagar, Pipalner Road,
Gandhi Nagar, Bhopal, Madhya Pradesh 462036, India


Lat 23.303626°

Long 77.342035°

23/03/23 10:45 AM GMT +05:30





 **GPS Map Camera**


Bhopal, Madhya Pradesh, India

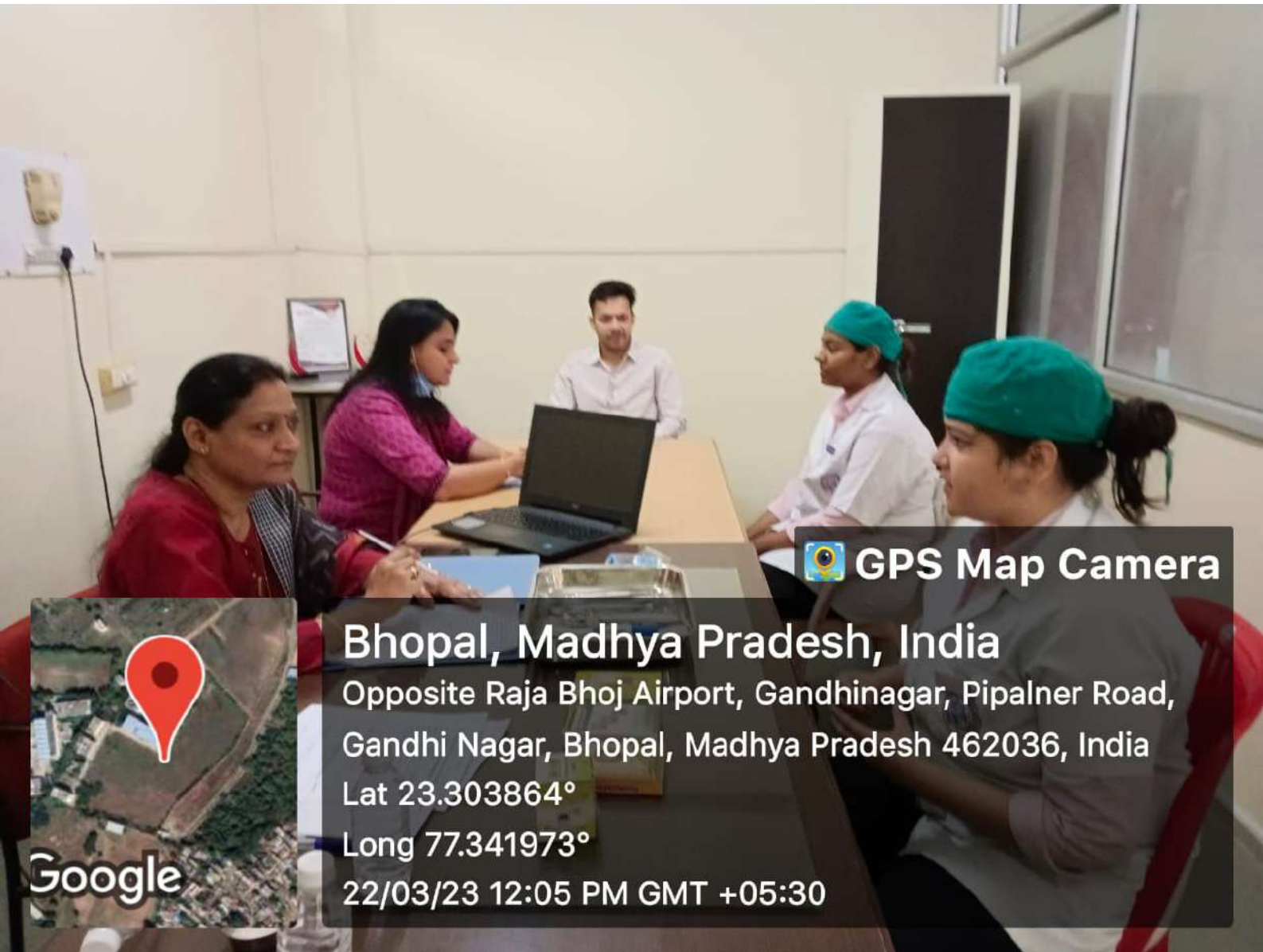Opposite Raja Bhoj Airport, Gandhinagar, Pipalner Road,
Gandhi Nagar, Bhopal, Madhya Pradesh 462036, India


Lat 23.30464°

Long 77.341786°

22/03/23 09:39 AM GMT +05:30





 **GPS Map Camera**

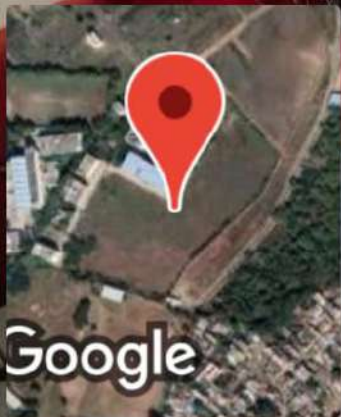
Bhopal, Madhya Pradesh, India

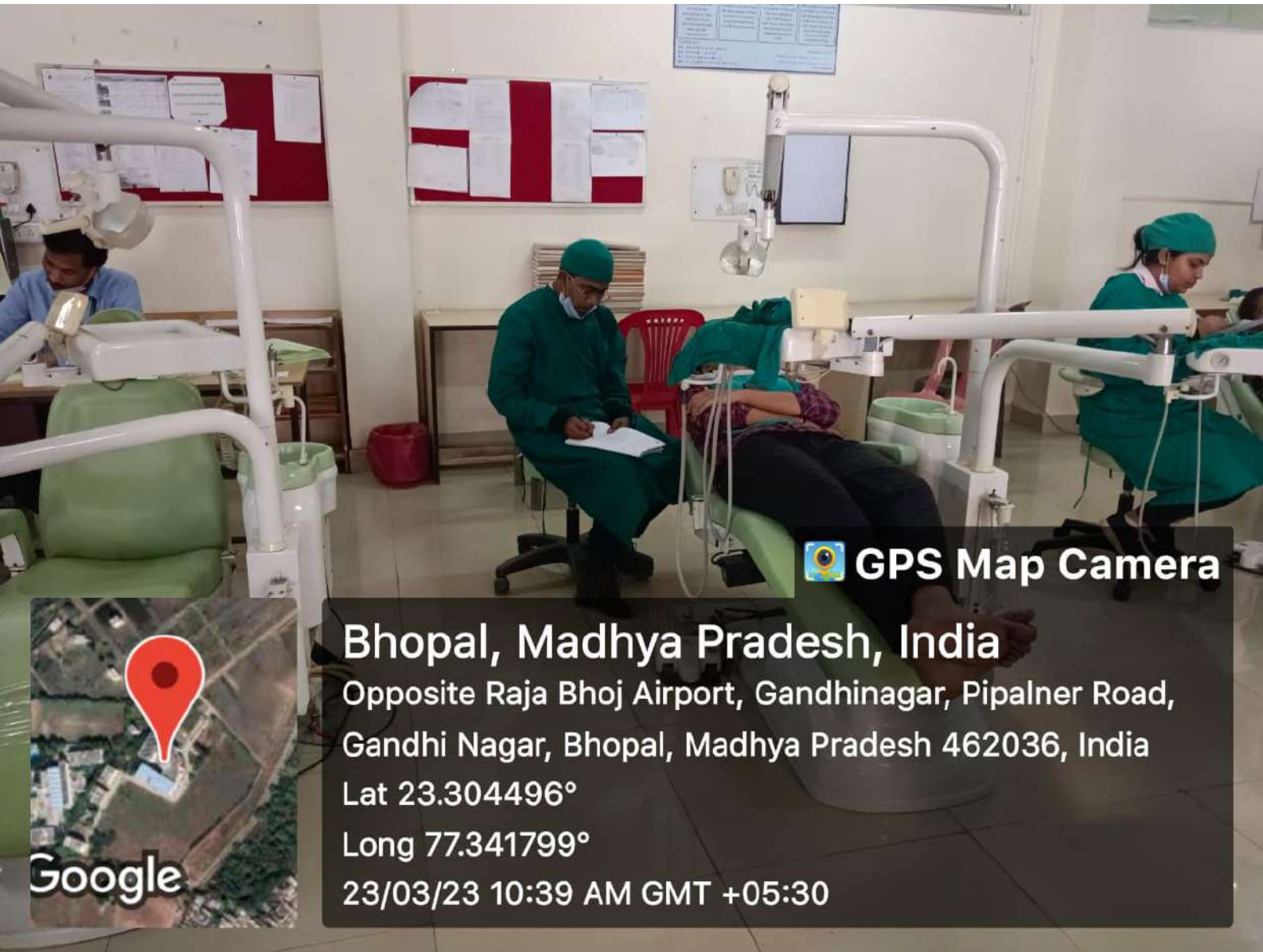Opposite Raja Bhoj Airport, Gandhinagar, Pipalner Road,
Gandhi Nagar, Bhopal, Madhya Pradesh 462036, India

Lat 23.303864°

Long 77.341973°

22/03/23 12:05 PM GMT +05:30





 **GPS Map Camera**

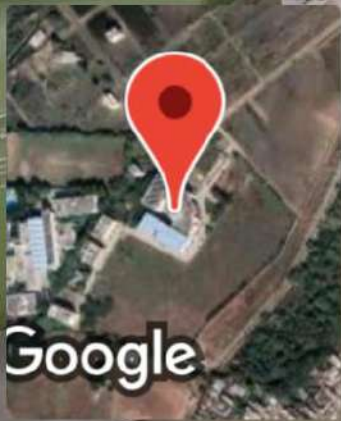
Bhopal, Madhya Pradesh, India

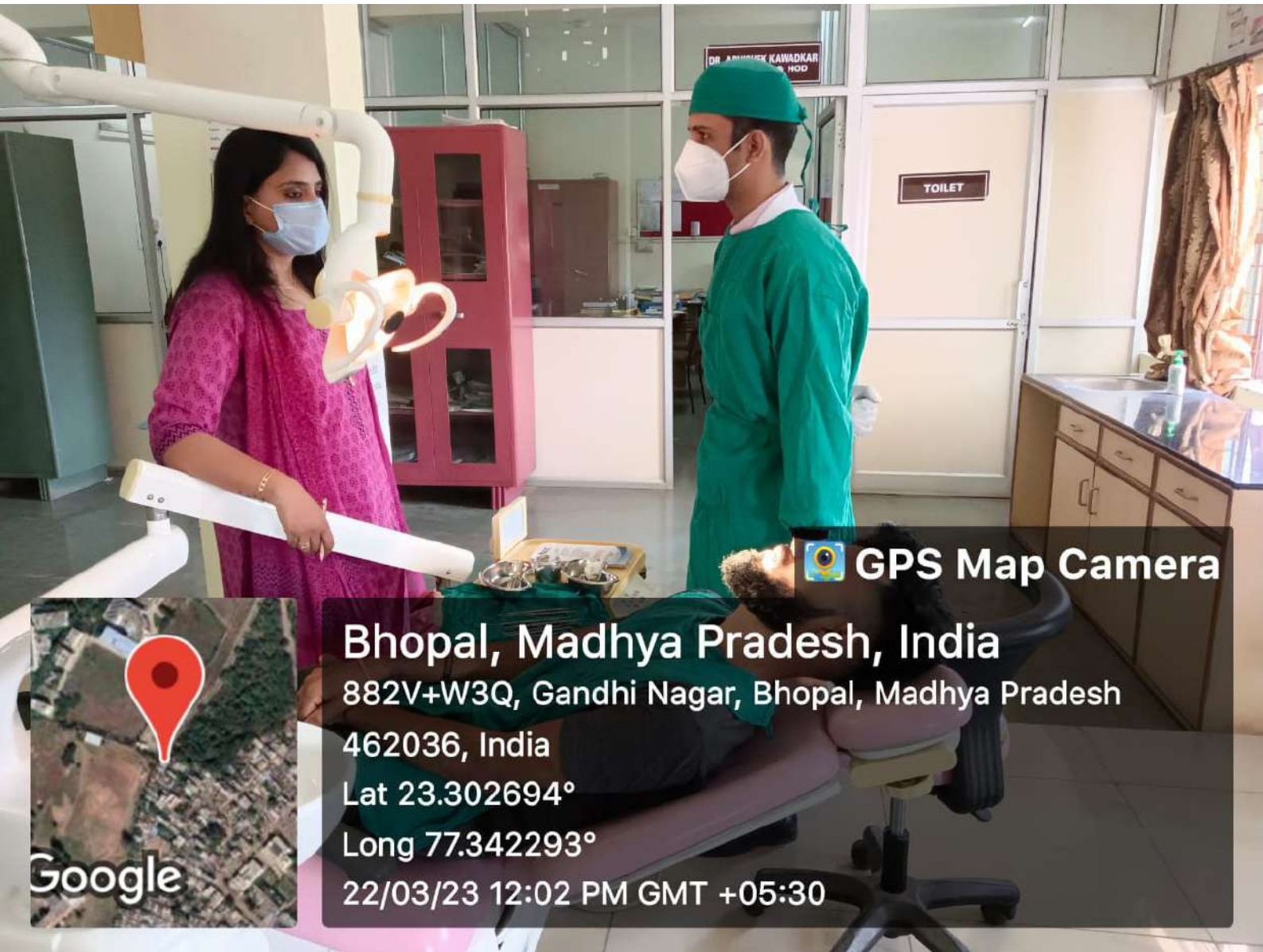
Opposite Raja Bhoj Airport, Gandhinagar, Pipalner Road,
Gandhi Nagar, Bhopal, Madhya Pradesh 462036, India


Lat 23.304496°

Long 77.341799°

23/03/23 10:39 AM GMT +05:30





 **GPS Map Camera**

Bhopal, Madhya Pradesh, India

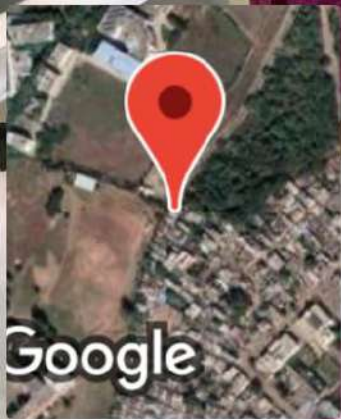
882V+W3Q, Gandhi Nagar, Bhopal, Madhya Pradesh

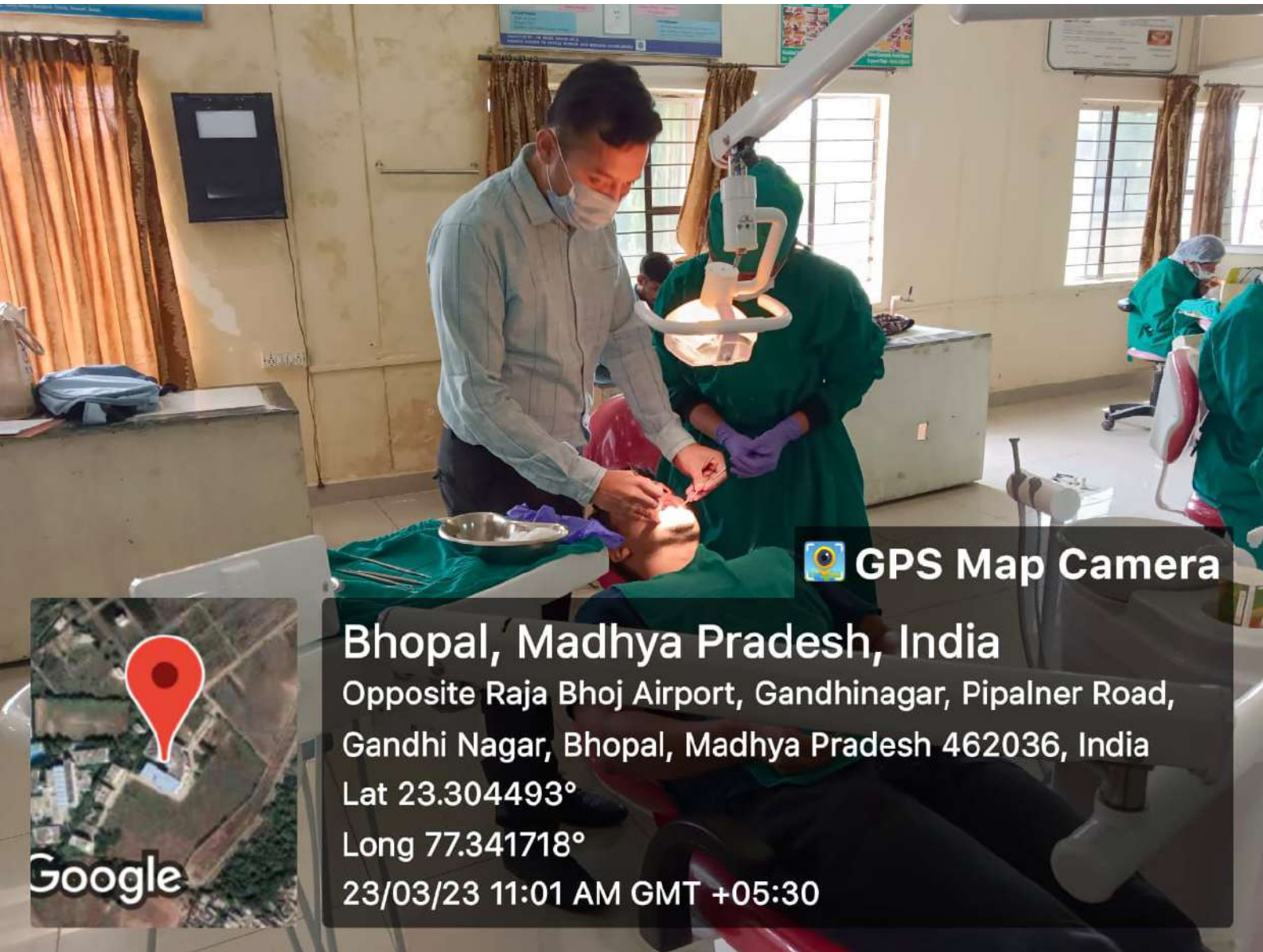
462036, India

Lat 23.302694°

Long 77.342293°

22/03/23 12:02 PM GMT +05:30





 **GPS Map Camera**

Bhopal, Madhya Pradesh, India

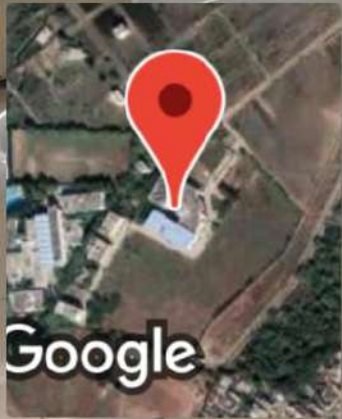Opposite Raja Bhoj Airport, Gandhinagar, Pipalner Road,


Gandhi Nagar, Bhopal, Madhya Pradesh 462036, India


Lat 23.304493°

Long 77.341718°

23/03/23 11:01 AM GMT +05:30





 **GPS Map Camera**

Bhopal, Madhya Pradesh, India

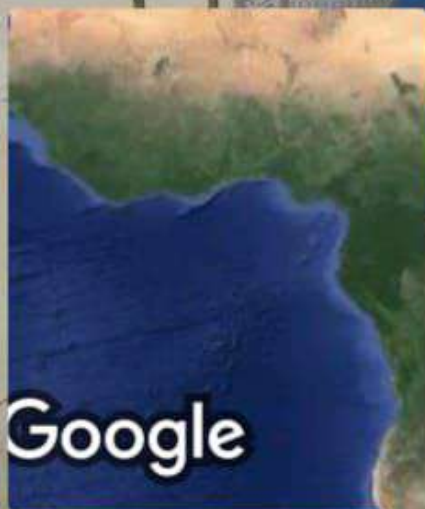Opposite Raja Bhoj Airport, Gandhinagar, Pipalner
Road, Gandhi Nagar, Bhopal, Madhya Pradesh

462036, India

Lat 23.304518°

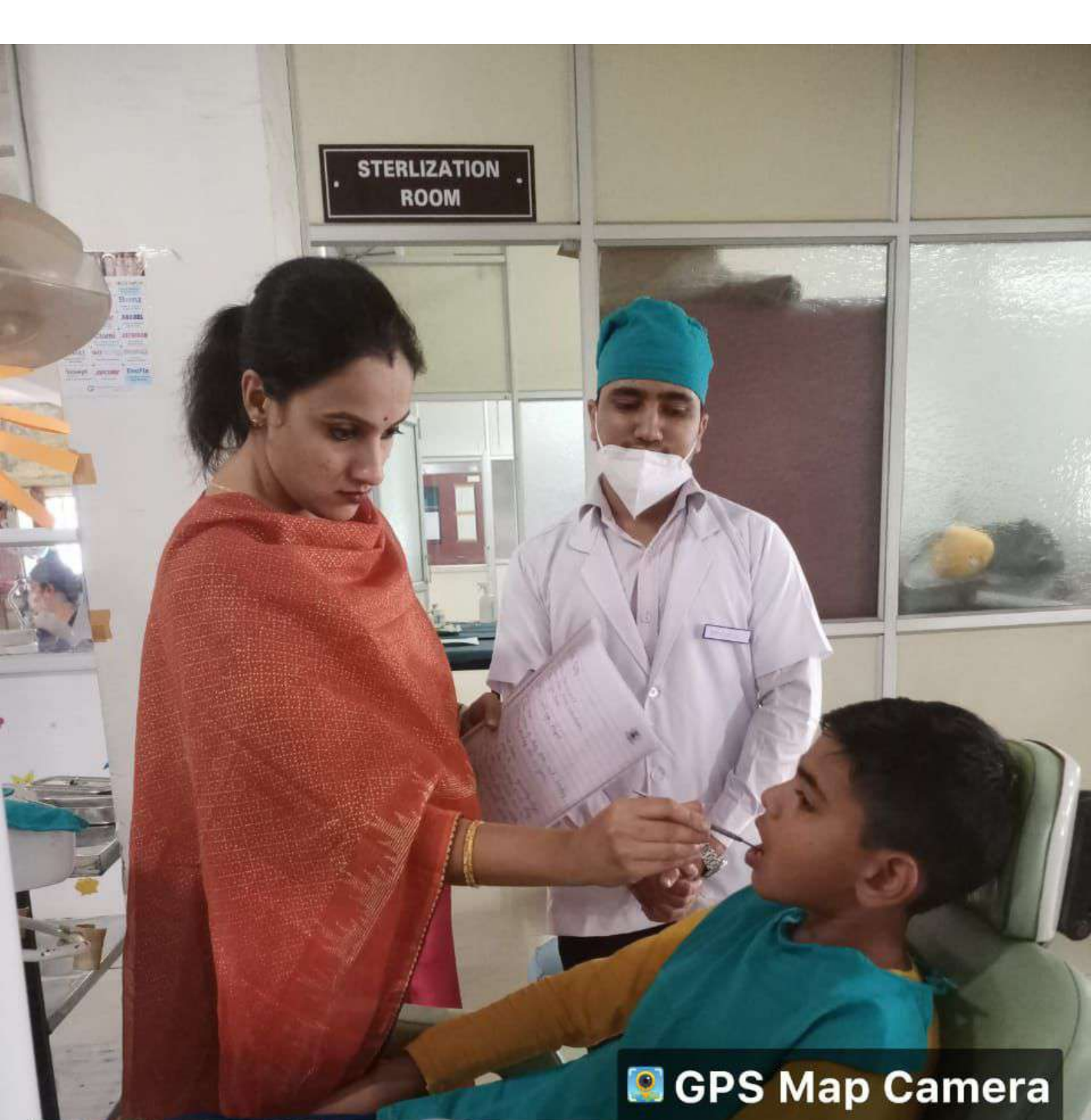
Long 77.3418°

20/03/23 12:46 PM GMT +05:30

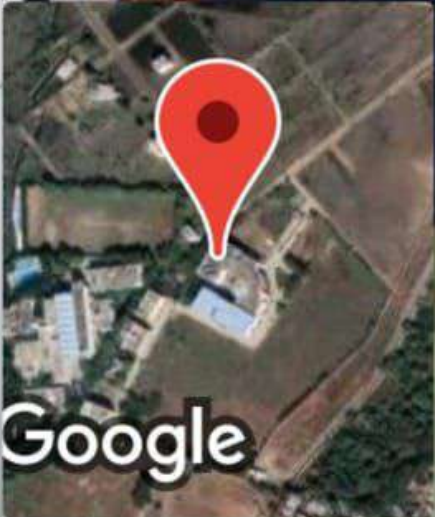


Google

STERILIZATION ROOM



 **GPS Map Camera**



Bhopal, Madhya Pradesh, India

Opposite Raja Bhoj Airport, Gandhinagar, Pipalner Road, Gandhi Nagar, Bhopal, Madhya Pradesh 462036, India

Lat 23.304715°

Long 77.341622°

21/03/23 11:37 AM GMT +05:30

Google